

# EPIFIBROIN 0039 POWDER

## in patients with autoimmune bullous diseases.

*Lidia Sacchelli 1, Camilla Loi 1, Annalisa Patrizi 1, Federico Bardazzi 1.*

*1. Dermatological Operative Unit, Department of Specialist, Diagnostic and Experimental Medicine, Policlinico S. Orsola – Malpighi, Bologna University*

The topical treatment of patients with autoimmune bullous diseases is fundamental. However, it is often difficult because it is necessary to resort to powerful topical steroids for months, or even years, with undeniable long-term side effects.

- We therefore decided to treat some patients with Epifibroin 0039 Powder, a medical device with a base of pure silk fibroin<sup>1</sup> (composed of amino acids compatible with skin and free from sericin), protected by a permanent antimicrobial<sup>2,3</sup>. Epifibroin 0039 Powder, derived from DermaSilk therapeutic apparel, favours the re-epithelisation of the treated skin and guarantees protection against any bacterial superinfections, which often complicate the lesions of these patients<sup>4</sup>.
- **The primary objective** was to evaluate the **OBJECTIVE parameters**: overall improvement of the surface treated, reduction of erythema, blisters, erosion/ulceration, grazes.
- **The second objective**, on the other hand, was to evaluate the **SUBJECTIVE parameters**: itching, burning and pain, but also the ease of use of the product and its tolerability. The patients were also asked about the reduction or non-assumption of pain-killers.

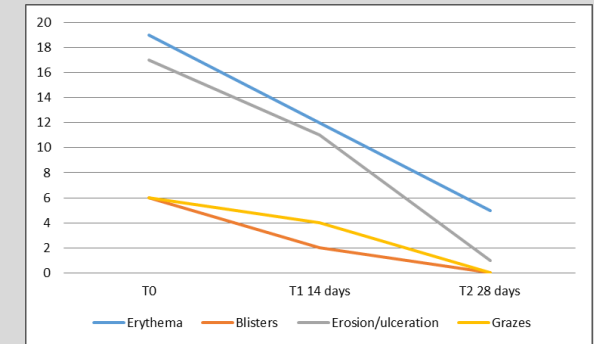
### THE PROTOCOL.

- After written informed consent, 10 adult patients of both sexes were enrolled from those attending the Centre for Autoimmune Bullous Diseases at the Policlinico Sant'Orsola Malpighi in Bologna.
- All the patients had received a clinical, histological and serological diagnosis of autoimmune disease and, at the time of enrolment, the disease was active and localised in different areas of the skin depending on the patient.
- Each patient applied Epifibroin 0039 Powder once a day on the erosive lesions after thorough cleaning with lukewarm water. If necessary, the patient wore specific DermaSilk therapeutic clothing.
- Two follow-up visits were established, at 14 (T1) and 28 (T2) days. At the time enrolment and at T1 and T2, we assessed the objective parameters: percentage of body surface affected by the pathology, erythema, blisters, erosion/ulceration, grazes, assigning a value from 0 to 3 (absent, slight, moderate, severe) as shown in Table 1. We also recorded the improvement of the treated surface and scarring with values from 0 for none, 1 for slight, 2 for moderate, 3 for high. The subjective parameters itching, burning and pain were measured, assigning a score from 0 for absent to 10 for intolerable.

SCORE	Erythema			Blisters			Erosion / ulceration			Grazes		
	TO	T1	T2	TO	T1	T2	TO	T1	T2	TO	T1	T2
0	0	0	5	6	8	10	2	3	9	6	7	10
1	2	9	5	2	2	0	0	4	1	2	2	0
2	7	0	0	2	0	0	7	2	0	2	1	0
3	1	1	0	0	0	0	1	1	0	0	0	0
TOTAL	19	12	5	6	2	0	17	11	1	6	4	0

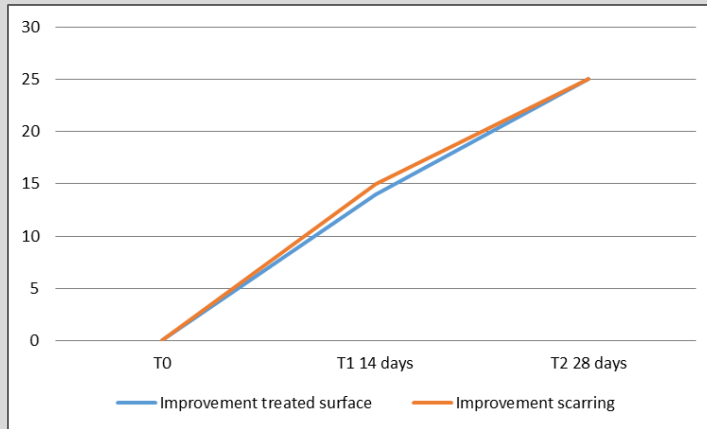
**Table 1.** Number of patients, score assigned to the objective parameters, at enrolment, after 14 days and after 28 days.

**Graph 1.** Reduction of objective parameters.



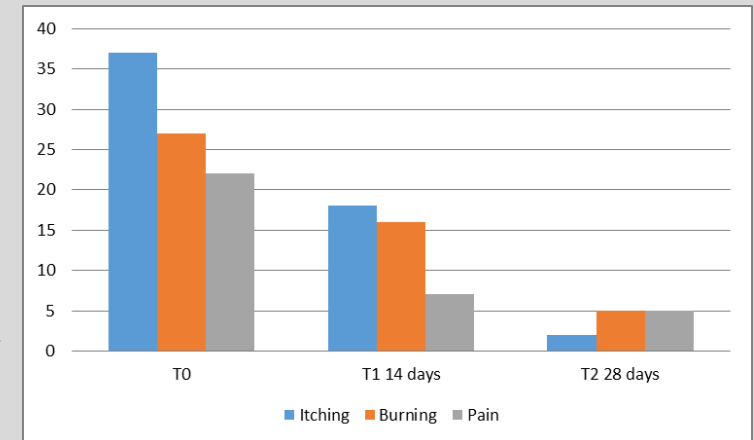
## THE RESULTS

- In all 10 patients, Epifibroin 0039 Powder allowed an improvement of the treated surface and of scarring (Graph 2), it was well tolerated and no difficulty was found in its use because it is simple to apply, especially in certain areas, compared to the traditional treatment. All the objective parameters showed a rapid reduction compared to the initial values within the 14-day follow-up, and cleared up almost completely before T2 (Graph 1). With regard to the subjective parameters of itching, burning and pain associated with the lesions, at T1 the patients reported a first important reduction, which then continued until the second and last follow-up (Graph 2). They also recorded a reduction in the use of pain-killers.



**Graph 2.** Improvement of the skin.

**Graph 3.** Reduction of subjective parameters.



## CONCLUSION

- In the light of the results obtained, we consider Epifibroin 0039 a valid aid in the topical treatment of autoimmune bullous diseases, alone or in combination with a topical steroid, in order to reduce its inevitable long-term side-effects.

1. AL.PRE.TEC. EPIFIBROIN 0039 dressing and powder, medical device class IIb, General Information of the product. 2015.

2. Sambri V, In vitro evaluation of the bio-activity of different fabrics for underwear against Lactobacillus acidophilus, Staph. Epidermidis, Staph. Aureus and Candida albicans. Depart. of Haem, Oncol, Microb, Bologna University; Poster Presentation EAACI 2009, Warsaw.

3. Mandrioli P et al. Chemical test: certifies that the polymerized antimicrobial on DermaSilk silk knitwear does not leach. CNR- Istituto ISAC- Bologna

4. El Hachem M, Zambruno G, Bourdon-Lanoy E et al. "Multicentre consensus recommendations for skin care in inherited epidermolysis bullosa" Orphanet Journal of Rare Diseases 2014; 9:76.